

Notes from the Field

The First Imported Case of Monkeypox in the Mainland of China — Chongqing Municipality, China, September 16, 2022

Hua Zhao^{1,2,&}; Wenling Wang^{3,&}; Li Zhao³; Sheng Ye^{1,2}; Jingdong Song³; Roujian Lu³; Hua Zong⁴; Changcheng Wu³; Wei Huang^{1,2}; Baoying Huang³; Yao Deng³; Ruhan A³; Wujuan Xie^{1,2}; Li Qi¹; Wenbo Xu³; Hua Ling^{1,2,#}; Wenjie Tan^{3,#}

Monkeypox is a zoonotic viral disease caused by the monkeypox virus (MPXV), and historically, all outbreaks have been linked to Africa; however, monkeypox has been posing an alarming challenge to the world in 2022 (1) as approximately 60,000 cases have been reported in more than 100 nations and regions worldwide (2). Currently, many cases of monkeypox were identified in many nonendemic countries outside of Central and West Africa, and human-to-human transmission has occurred frequently, especially among men who have sex with men (MSM) presenting new clinical symptoms similar to syphilis and other sexually transmitted infections (3). The World Health Organization (WHO) has declared monkeypox a Public Health Emergency of International Concern (PHEIC) on July 23, 2022. Here, we report the first imported case of monkeypox in the mainland of China on September 16, 2022.

A 29-year-old salesman of Chinese nationality visited Germany during September 2–8, 2022, and had MSM behavior in Berlin on September 2. He subsequently traveled to Spain, and then returned Chongqing Municipality, China on September 14, 2022. The man suffered from dry and itchy throat and had a fever on September 9 with red rashes and pustules displayed on his right thigh (Figure 1A). On September 11, he visited a private clinic and took anti-inflammatory medication. On September 14, he was isolated in a coronavirus disease 2019 (COVID-19) quarantine spot in Chongqing. He self-reported that he displayed monkeypox-like clinical manifestations and was then identified as a suspected case of monkeypox by Chongqing CDC.

Clinical specimens, including blister fluid, nasopharyngeal and oropharyngeal swabs, and a blood sample were collected on September 14, and the primary screening of MPXV based quantitative real-time polymerase chain reaction (qPCR) showed positive results among these specimens, which were then sent to National Institute for Viral Disease

Control and Prevention (IVDC), China CDC on September 16. Several qPCR (4–5) and whole genome sequencing (DNBSEQ-G99 by MGI Tech Co., Ltd. China and Oxford/Nanopore) were performed. The qPCR results showed that monkeypox genome and West Africa strain was detected as positive in the specimens of the case (Table 1). In addition, the swab of blister fluid was directly used for transmission electron microscopy. The result revealed that typical mulberry-shaped particles were visualized with diameters ranging from 150 to 200 nm, a characteristic of MPXV (Figure 1B). Gene sequencing suggests that MPXV strain in this case (China-CQ202209) belongs to B.1 branch of the West African lineage, and it was highly homologous to strains from Germany collected on June 21, 2022 (GISAID ID: EPI_ISL_13889435) (Figure 1C). These results confirmed the first imported monkeypox case in the mainland of China, making this the fifth confirmed monkeypox infection in humans reported in China. Other imported cases of monkeypox human infection were reported in Taiwan, China (6) and Hong Kong Special Administrative Region, China (7).

Neglected zoonotic monkeypox is now back in the spotlight worldwide and the alarm for China's prevention and control has been sounded to prevent MPXV import and transmission (1). The Chinese technical plan for monkeypox prevention and control has been released for guidance and reference since July 1, 2022 (8). It is essential to control the human-to-human transmission of monkeypox through early detection, early reporting, early isolation, and early treatment. It is necessary to further strengthen symptomatic surveillance in travelers and immigrants from endemic and epidemic areas. In addition, the keys to control the epidemic of MPXV include the following: enhancing health education among general populations and strengthening the management of both high-risk people (such as inbound travelers who have had close contact with infected persons or wildlife) and key demographics (such as MSM).

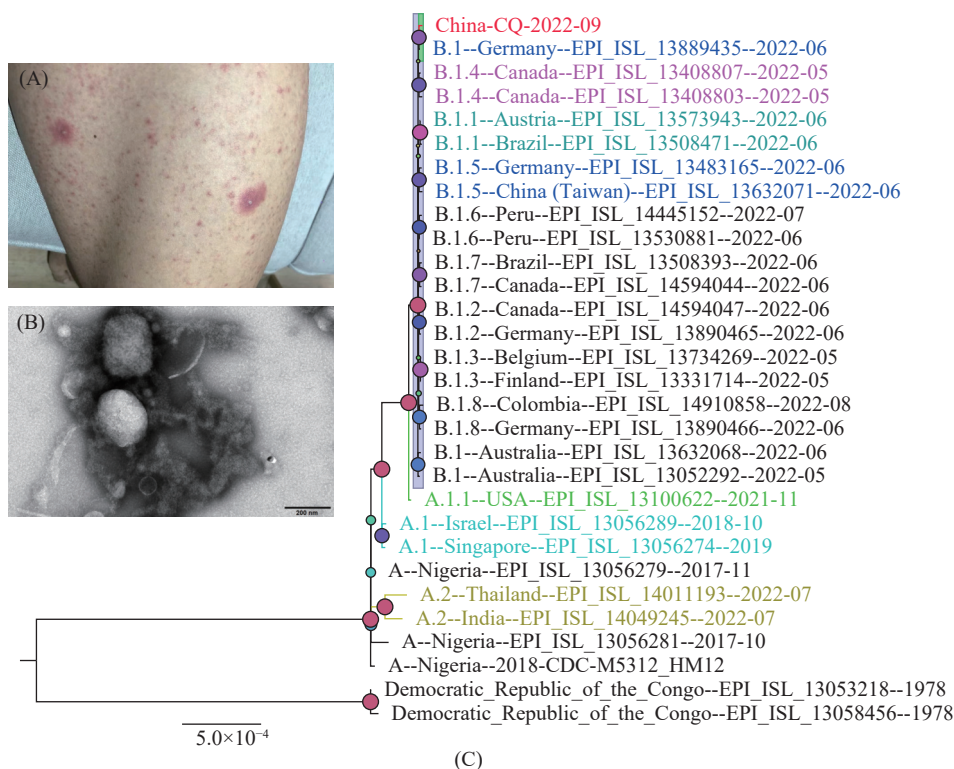


FIGURE 1. Clinical manifestations and laboratory evidence of the first imported monkeypox case in the mainland of China. (A) Rash and pustules displayed on the right thigh of the imported case. (B) Electron microscopy of MPXV-CQ-2022 in the swabs of blister fluid. (C) Phylogenetic tree based on the full-length genome sequences of MPXV.

TABLE 1. Detection of MPXV among the specimens of Chongqing imported case by qPCR.

Specimen	Ct-F3L	Ct-J2R	Ct-D14L	MPXV	West Africa strain of MPXV
Blister fluid swab	20.76	ND	ND	Positive	ND
Oropharyngeal swab	27.81	31.29	Neg	Positive	Positive
Nasopharyngeal swab	31.00	33.25	Neg	Positive	Positive
Blood	33.65	35.54	Neg	Positive	Positive

Abbreviation: MPXV=monkeypox virus; qPCR=quantitative real-time polymerase chain reaction; ND=not determined; Neg=negative.

doi: 10.46234/ccdcw2022.175

Corresponding authors: Hua Ling, linghuax@163.com; Wenjie Tan, tanwj@ivdc.chinacdc.cn.

¹ Chongqing Municipal Center for Disease Control and Prevention, Chongqing Municipality, China; ² Chongqing Municipal Key Laboratory for High Pathogenic Microbes, Chongqing Municipality, China; ³ National Institute for Viral Disease Control and Prevention, Chinese Center for Disease Control and Prevention, Beijing Municipality, China; ⁴ Nan'an Center for Disease Control and Prevention, Nan'an District, Chongqing Municipality, China.

© Joint first authors.

Submitted: September 17, 2022; Accepted: September 18, 2022

REFERENCES

1. Tan W, Gao GF. Neglected Zoonotic Monkeypox in Africa but Now Back in the Spotlight Worldwide. *China CDC Wkly* 2022. <http://dx.doi.org/10.46234/ccdcw2022.166>.

2. CDC. 2022 monkeypox outbreak global map. 2022. <https://www.cdc.gov/poxvirus/monkeypox/response/2022/world-map.html> [2022-9-15].

3. Thornhill JP, Barkati S, Walmsley S, Rockstroh J, Antinori A, Harrison LB, et al. Monkeypox Virus Infection in Humans across 16 Countries — April–June 2022. *N Engl J Med* 2022;387(8):679 – 691. <http://dx.doi.org/10.1056/NEJMoa2207323>.

4. Ye F, Song JD, Zhao L, Zhang Y, Xia LX, Zhu LW, et al. Molecular Evidence of Human Monkeypox Virus Infection, Sierra Leone. *Emerg Infect Dis* 2019;25(6):1220 – 2. <http://dx.doi.org/10.3201/eid2506.180296>.

5. Li Y, Zhao H, Wilkins K, Hughes C, Damon IK. Real-time PCR assays for the specific detection of monkeypox virus West African and Congo Basin strain DNA. *J Virol Methods* 2010;169(1):223 – 7. <http://dx.doi.org/10.1016/j.jviromet.2010.07.012>.

6. Yang ZS, Lin CY, Urbina AN, Wang WH, Assavalapsakul W, Tseng SP, et al. The first case of monkeypox virus infection detected in Taiwan: awareness and preparation. *Int J Infect Dis* 2022;122:991 – 5. <http://dx.doi.org/10.1016/j.ijid.2022.07.051>.

7. WHO. 2022 Monkeypox Outbreak: Global Trends. 2022. https://worldhealthorg.shinyapps.io/mpx_global/#2_Global_situation_update [2022-9-17].

8. Health Emergency Response Office. Notice of the General Office of the National Health Commission on the issuance of the Technical Guidelines for monkeypox Prevention and Control (2022 edition). 2022. <http://www.nhc.gov.cn/yjb/s3577/202207/acd6016aaca543e29c16deb9b5ea3303.shtml>. [2022-9-17]. (In Chinese).